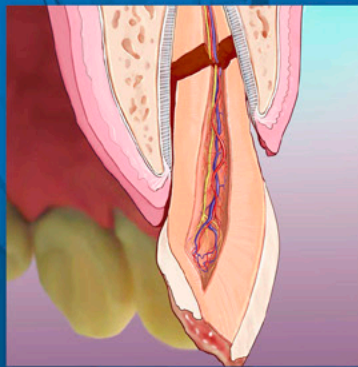


# ENDODONTICS



*Colleagues for  
Excellence*

Summer 2014

*The Treatment of  
Traumatic Dental Injuries*



Published for the Dental Professional Community by the  
***American Association of Endodontists***

[www.aae.org/colleagues](http://www.aae.org/colleagues)

When treating dental trauma, the timeliness of care is key to saving the tooth in many cases. It is, therefore, important for all dentists to have an understanding of how to diagnose and treat the most common dental injuries. This is especially critical in the emergency phase of treatment.

Proper management of dental trauma is most often a team effort with general dentists, pediatric dentists or oral surgeons on the front line of the emergency service, and endodontic specialists joining the effort to preserve the tooth with respect to the pulp, pulpal space and root. An informed and coordinated effort from all team members ensures that the patient receives the most efficient and effective care.

Recently, a panel of expert members of the American Association of Endodontists prepared an updated version of *Guidelines for the Treatment of Traumatic Dental Injuries* (1, 2). These guidelines were based, in part, on the current recommendations of the International Association of Dental Traumatology (see [www.iadt-dentaltrauma.org](http://www.iadt-dentaltrauma.org) for more information). This issue of *ENDODONTICS: Colleagues for Excellence* provides an overview of the AAE guidelines; the complete guidelines are available for free download at [www.aae.org/clinical-resources/trauma-resources.aspx](http://www.aae.org/clinical-resources/trauma-resources.aspx).

The benefit of adhering to guidelines for treatment of dental trauma was recently shown in a study by Bucher et al. (3). The study found that, compared to cases treated without compliance to guidelines, cases that adhered to guidelines produced more favorable outcomes, including significantly lower complication rates. The study also found that early follow-up visits were essential to ensure prompt treatment of complications when they arose (3).

### **Emergency Care**

Prior to any treatment, one must evaluate the injury thoroughly by careful clinical and radiographic investigation. It is recommended to follow a checklist to ensure that all necessary information regarding the patient and the injury is gathered, including:

1. Patient's name, age, sex, address and contact numbers (include weight for young patients)
2. Central nervous system symptoms exhibited after the injury
3. Patient's general health
4. **When, where** and **how** the injury occurred
5. Treatment the patient received elsewhere
6. History of previous dental injuries
7. Disturbances in the bite
8. Tooth reactions to thermal changes or sensitivity to sweet/sour
9. If the teeth are sore to touch or during eating
10. If the patient is experiencing spontaneous pain in the teeth

Once all of this information is gathered, a diagnosis can be made and appropriate treatment rendered. If the injured individual is not a patient of record, all necessary demographic information should be gathered as soon as the patient arrives and prior to any assessment. In the case of avulsion and the tooth being out of its socket, one should immediately place the tooth in a physiological solution of specialized media (such as Hank's Balanced Salt Solution™) or milk, or saline if those are not available. Only after the tooth is secured in solution should one obtain the patient's information. Once the patient is seated in the dental chair, it is necessary to do a quick central nervous system (CNS) evaluation before proceeding with further assessments.

Often, the dentist is the first healthcare provider to see the patient after a head injury (any dental trauma is, by definition, a head injury!) and must assess the risk of concussion or hemorrhage. It has been estimated by a meta-analysis that the prevalence of intracranial hemorrhage after a mild head injury is 8%, and the onset of symptoms can be delayed for minutes to hours (4). The most common signs of serious cerebral concussion or hemorrhage are loss of consciousness or post-traumatic amnesia. Nausea/vomiting, fluids from the ear/nose, situational confusion, blurred vision or uneven pupils, and difficulty of speech and/or slurred speech may also indicate serious injury (5).

Once the patient has been cleared of any CNS issues, the dental trauma should be assessed. The key is to obtain comprehensive information about the injury and, to do so, one must conduct thorough extraoral and intraoral clinical exams as well as appropriate radiographic evaluations.

The new AAE guidelines recommend taking one occlusal and two periapical radiographs with different lateral angulations for all dental injuries, including crown fractures. If cone beam-computed tomography is available, it should be considered for more serious injuries like crown/root, root and alveolar fractures, as well as all luxation injuries.

Additionally, sensibility tests should be conducted on all teeth involved as well as opposing teeth. Cold testing is recommended over electric pulp testing in young individuals (6). Both testing methods should be considered, however, especially when there is no response to one of the two. The pulp might be nonresponsive for several weeks after a traumatic injury, so a pulp test should be done at every follow-up appointment until a normal response is obtained (7).

Once the diagnosis is confirmed and more serious complications such as CNS and jaw or other facial bone fractures have been ruled out, the emergency phase of the treatment needs to be initiated. **The aim of treating dental trauma should be to either maintain or regain pulpal vitality in traumatized teeth.** This is because dental trauma most frequently occurs in pre-teens or young teens in whom the teeth have not yet fully developed, and root development will cease without a vital pulp.

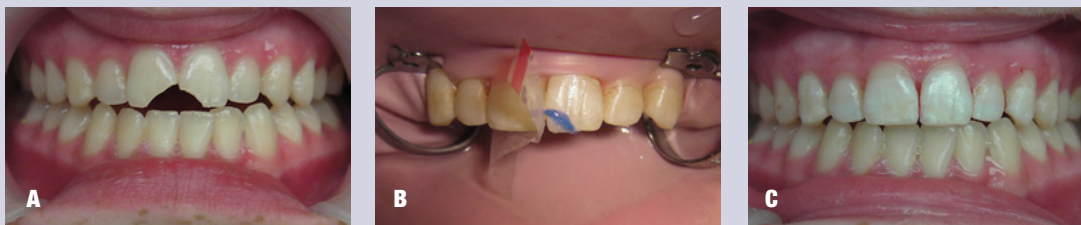## Clinical Examples

Dental trauma can be roughly divided into two groups: fractures and luxation injuries. The fractures are then further divided by type: crown, crown-root and root fractures. If the pulp is exposed to the oral environment, it is called a complicated fracture; if not exposed, it is called an uncomplicated fracture.

### Crown Fractures

The first thing to do in any crown or crown-root fracture is to look for the broken-off tooth fragment. With modern bonding technology it is possible to rebond the fragment to the tooth, which is esthetically the best solution. Prior to reattaching the tooth fragment, the remaining dental thickness immediately covering the pulp needs to be assessed radiographically and clinically. If there is at least 0.5 mm of the dentin remaining, there is no need to cover it with a protective liner. If it is estimated that the remaining dentin is less than 0.5 mm, it is advisable to cover the deepest part, closest to the pulp, with a cavity liner, and then dimple the fragment accordingly (8, 9). If the tooth fragment was kept dry, it should be rehydrated in distilled water or saline for 30 minutes prior to reattachment. This process will increase its bonding strength (10) (Figure 1).

In a complicated fracture, the goal is to create a bacteria-tight seal to protect the pulp, after ensuring that the pulpal wound is



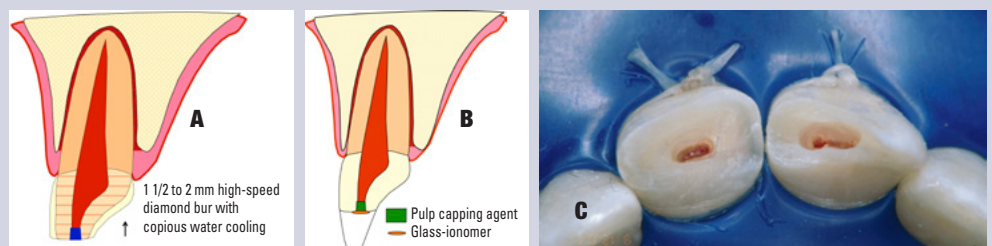
**Fig. 1.** (A) Clinical case of two uncomplicated crown fractures in which the two broken pieces were located and reattached. (B) After the two pieces had been attached, a chamfer was cut along the fracture line and additional composite cured in place. This will both increase the strength of the attachment and better hide the fracture line (C).

clean and all inflamed tissue removed (11, 12). The two best capping materials available today are calcium hydroxide and mineral trioxide aggregate (MTA) (13, 14), but newer bioceramic materials are showing promise for this application. It is advisable to create a 1-2 mm reservoir

into the pulp with a high-speed diamond bur and copious water cooling, place the capping material, and then either reattach the tooth fragment or restore the crown with a composite resin material (Figure 2).

### Crown-Root Fractures

One of the more challenging types of fracture to treat is the crown-root fracture because the fracture margin has to be exposed around the tooth/crown to properly restore the tooth. This can be accomplished by gingivectomy if the fracture line is in the sulcus. In more extreme cases, the tooth will have to be



**Fig. 2.** (A) Schematic diagram of minimal pulpotomy, where an approximately 2-mm reservoir is cut with a high-speed diamond bur and copious water cooling and calcium hydroxide mixed with sterile water placed. (B) Glass ionomer or a protective liner is placed over the pulp capping agent to ensure it stays in place during etching and bonding. (C) Clinical pictures of the minimal pulpotomy. *Schematic drawings courtesy of Dr. Sigurdsson.*

extruded with orthodontic forces or surgically repositioned. In the emergency session, if the pulp is exposed, it needs to be protected in the same fashion as complicated crown fractures. If it is not exposed, all accessible exposed dentin areas should be covered for the patient's comfort.

Pulpal survival for all these fracture types is generally good; however, endodontic treatment may be indicated later (15, 16). Therefore, it is of utmost importance that a recall schedule is followed and that the teeth involved in the trauma are tested every time. Tables 1 and 2 outline the recommended recall rates for most common dental injuries. It is not uncommon for there to be no response to vitality tests for up to three months, and a lack of response to vitality tests does not always indicate that root canal treatment is needed – especially in young and immature teeth. Rather, it is advisable to look for at least one other sign of pulpal necrosis, like vestibule swelling, periapical lesions and/or dramatic color change of the crown. If no signs exist, continue to monitor the patient at regular appointments every three months, for up to one year.

**Table 1. Follow-Up Procedures for Fractured Permanent Teeth and Alveolar Fractures**

TIME	Crown Fracture		Crown-Root Fracture		Root Fracture	Alveolar Fracture
	Uncomplicated	Complicated	Uncomplicated	Complicated		
4 Weeks					Splint removal*, clinical and radiographic control	Splint removal and clinical and radiographic controls
6-8 Weeks	Clinical and radiographic control	Clinical and radiographic control	Clinical and radiographic control	Clinical and radiographic control	Clinical and radiographic control	Clinical and radiographic control
4 Months					Splint removal**, clinical and radiographic control	Clinical and radiographic control
6 Months					Clinical and radiographic control	Clinical and radiographic control
1 Year	Clinical and radiographic control	Clinical and radiographic control	Clinical and radiographic control	Clinical and radiographic control	Clinical and radiographic control	Clinical and radiographic control
Yearly for 5 Years					Clinical and radiographic control	Clinical and radiographic control

*\*Splint removal in apical third and mid-root fractures; \*\*Splint removal with a root fracture near the cervical area*

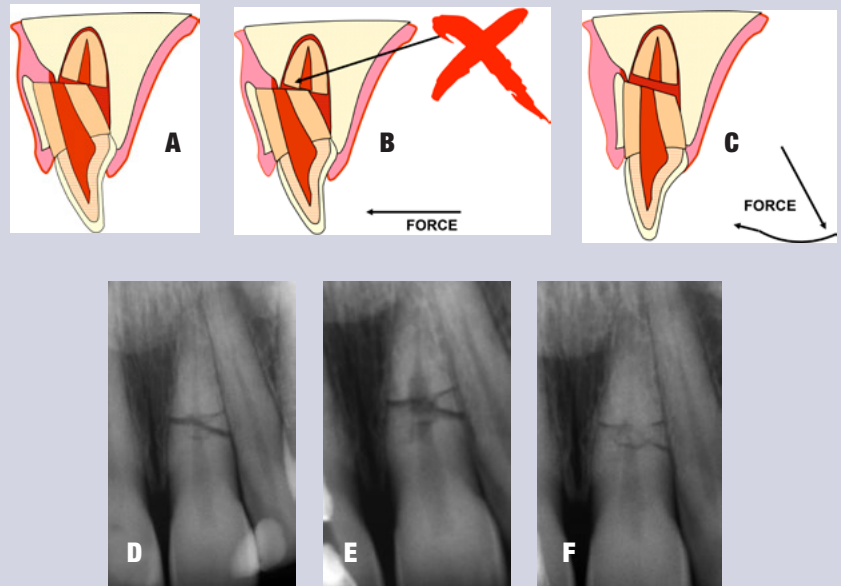
**Table 2. Follow-Up Procedures for Luxated Permanent Teeth**

TIME	Concussion/Subluxation	Extrusion	Lateral Luxation	Intrusion
2 Weeks	Splint removal (if applied for subluxation) Clinical and radiographic examination	Splint removal Clinical and radiographic examination	Clinical and radiographic examination	Clinical and radiographic examination
4 Weeks	Clinical and radiographic examination	Clinical and radiographic examination	Splint removal Clinical and radiographic examination	Splint removal Clinical and radiographic examination
6-8 Weeks	Clinical and radiographic examination	Clinical and radiographic examination	Clinical and radiographic examination	Clinical and radiographic control
6 Months	Clinical and radiographic examination	Clinical and radiographic examination	Clinical and radiographic examination	Clinical and radiographic examination
1 Year	Clinical and radiographic examination	Clinical and radiographic examination	Clinical and radiographic examination	Clinical and radiographic examination
2-5 Years	Yearly up to 5 years	Yearly up to 5 years	Yearly up to 5 years	Yearly up to 5 years



### Root Fractures

The pulp is affected in all root fractures. However, if the fragments are approximated soon after the fracture, there is a good chance that no endodontic treatment is necessary, just observation. With good approximation, it is likely that the pulp will revascularize across the fracture regardless of the age of the patient (17, 18) (Figure 3). A recent retrospective study included assessment of splinting type and time of root fracture. The study determined that, if the cervical portion of the tooth is stable once the two pieces have been approximated, no splint or a flexible splint for two weeks produces the best treatment outcome (2, 18). Longer splinting time is only recommended when the fracture is close to the cervical area.



**Fig. 3.** (A) Schematic drawing of a common situation after root fracture – the crown portion is displaced inward towards the palate and the fractured piece is stuck to the facial cortical plate. (B) It is impossible to move the coronal portion back to its original location without releasing it from the cortical plate. (C) This is accomplished by pulling the coronal portion down and then repositioning it. (D) A periapical radiograph of a root fracture a few hours after the injury. It was established that both fragments were in good approximation of each other. Splinting was done for two weeks. (E) At the nine-month recall, internal root resorption was noted, but no defect in the PDL or adjacent bone, indicating a “normal” healing process. (F) Five-year recall, no endodontic treatment was needed. Schematic drawings courtesy of Dr. Sigurdsson.

### Luxation Injuries

All luxation injuries will cause some damage to the periodontal ligament and, in some cases, the pulp as well. The immediate treatment is to limit further damage to the PDL and allow for the best possible healing. As with all dental injuries, follow-up is essential. Late complications, such as internal or external root resorptions, are relatively frequent and require endodontic treatment, especially in more severe injuries. In many of these cases, referral to an endodontist is advisable.

Luxation injuries are divided into subcategories, mainly by degree of severity.

The two mildest are termed “concussion” and “subluxation.” In those cases, the tooth is still in its original location, but is tender to percussion and/or, in the case of subluxation, has increased mobility. While no immediate treatment is needed for these injuries, follow-up is critical because the pulp may become necrotic, making endodontic intervention paramount.

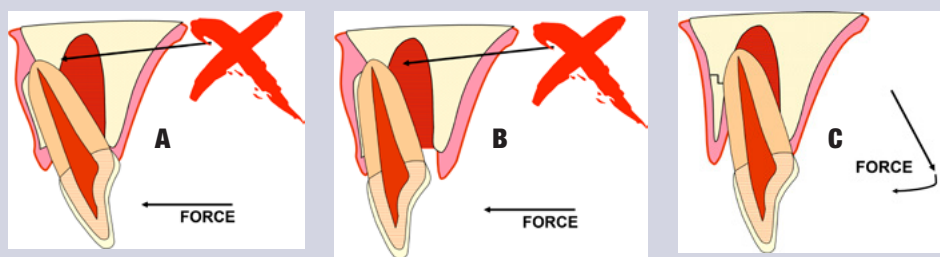
When trauma has moved the tooth out of its normal position, it needs to be replaced gently as soon as possible. The only exceptions are cases of intrusion when it might not be possible or advisable to manipulate the tooth immediately. When an immature tooth is intruded up to 7 mm, it is recommended to wait three weeks and watch for signs of re-eruption. If no signs exist, one can initiate orthodontic repositioning. For intrusion of more than 7 mm, surgical or orthodontic repositioning should be performed within three weeks. In the case of an intruded tooth with a closed apex, there is a possibility of re-eruption if the tooth is slightly intruded (less than 3 mm) and the patient is younger than 17 years old. If the tooth is not

moving after two to three weeks, however, orthodontic extrusion or extraction and reimplantation is recommended. If a tooth with a closed apex is intruded more than 3 mm, orthodontic or surgical repositioning should be performed within three weeks. The risk with all intrusions is that the intruded tooth may ankylose in the infraposition. Once that begins, the tooth may not be movable except possibly surgically. It is well to advise the patient and the parents/guardians that the long-term prognosis of an intruded tooth is unpredictable, as it is likely to eventually be lost due to ankylosis (19-21).

Splinting of a luxated tooth is only recommended for teeth that are still mobile after repositioning. In all types of trauma cases, a splint must allow for physiological movement (22, 23) (Figures 4

**Table 3. Splinting Time for Various Types of Injuries**

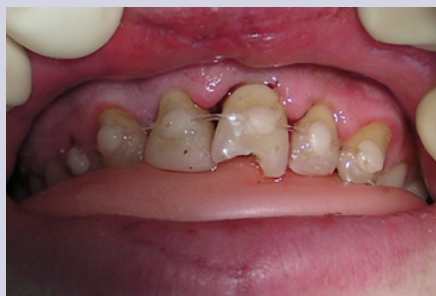Type of Injury	Splinting Time
Subluxation	2 weeks
Extrusive luxation	2 weeks
Avulsion	2 weeks
Lateral luxation	2 weeks
Intrusion	4 weeks
Root fracture (middle 1/3)	4 weeks
Alveolar fracture	4 weeks
Root fracture (cervical 1/3)	4 months



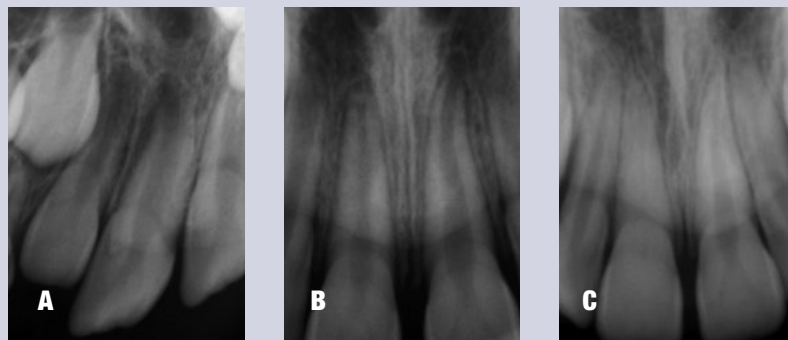**Fig. 4.** (A) In lateral luxation injuries of maxillary teeth, the apex is frequently pushed through the cortical plate facially. To reposition the tooth it has to be released prior to moving the crown forward (B) and (C). Schematic drawings courtesy of Dr. Sigurdsson.

and 5, and Table 3, regarding splinting time).

When assessing luxation trauma, it is important to consider the maturity of the apex. If it is still open, there is a chance that the pulp will survive the trauma or revascularize, allowing the growth of the tooth to continue (Figure 6).



**Fig. 5.** Once the tooth has been repositioned, the patient bites into a softened pink wax plate that had been previously rolled one or two times. This will ensure that the luxated (or avulsed) tooth stays in place while being splinted. In this case, a 16-pound fishing line was used as the splint on the luxated tooth.



**Fig. 6.** An immature tooth that was laterally luxated, as can be seen by the empty socket space around the apex on the radiograph (A). The tooth was repositioned and splinted for two weeks. (B) At the six-month recall there is good evidence that the apex is maturing and the pulp responds normally to cold. (C) At the three-year recall the pulp chamber is completely calcified; however, the tooth responds normally to EPT and there is no apical pathology.

If the apex is closed, endodontic treatment is likely needed. It is advisable to follow the patient closely (see Table 1) or refer him or her to an endodontist for further evaluation. Because of the injury to the PDL, rapid inflammatory root resorption can occur (within days or a few weeks) if the necrotic pulpal tissue becomes infected. For mature teeth diagnosed with necrotic pulps, placing calcium hydroxide for two to four weeks prior to obturation is recommended; however, one should allow the PDL to heal for two weeks before placement (see treatment for avulsion below). Apexification or revascularization is recommended for teeth with open apices (24, 25).

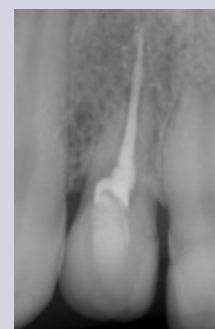It is important to remember that dental injuries do not always fall into one group or category, but often a combination of several categories. Injuries in multiple categories will impact the outcome. For example, it was recently demonstrated that the existence of a concurrent luxation injury with an uncomplicated crown fracture and complete root development are significant risk factors of pulp necrosis (26).

### Avulsion

The time outside of the socket for an avulsed tooth is the most critical factor its survival. If the tooth is replanted within 30 minutes, or alternatively kept in a physiological solution of specialized media or milk for a few hours, it has a fairly good prognosis (27, 28). If the tooth has been dry for more than one hour, the periodontal ligament cannot be expected to survive and the tooth will likely become ankylosed (Figure 7). Once reimplanted, most teeth need to be stabilized with a physiological splint for two weeks (29).

If the avulsed tooth has an open apex and was reimplanted within the hour, there is a possibility that the pulp will revascularize. In this case, delaying endodontic treatment at the emergency stage is recommended. Endodontic treatment should only be performed later if signs of pulpal necrosis, root resorption and/or arrested root development are confirmed.

In the case of a closed apex, revascularization is not expected. Therefore, endodontic treatment must be initiated two weeks after the tooth is reimplanted, and prior to removal of the splint. Treatment should not be initiated earlier as any further manipulation of the tooth prior to or immediately after reimplantation can cause further damage to the PDL. In addition, it has been shown that placing calcium hydroxide as an



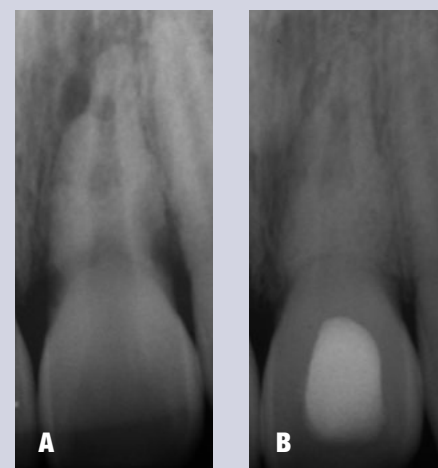
**Fig. 7.** Ankylosis or replacement root resorption, in which the root structure is lost and replaced by bone. Note that no apparent PDL space is seen.

intracanal medicament immediately after reimplantation will promote inflammation that can lead to PDL damage (30). If the tooth had been kept dry longer than 60 minutes, performing root canal treatment prior to replantation is indicated (31).

After the emergency situation has been managed and the tooth/teeth stabilized, the second phase begins, in which the pulpal condition and likelihood of root resorption have to be carefully evaluated and the patient followed over a period of months, if not years. A follow-up timeline is essential to allow for intervention if signs of complications appear. In such cases, the expertise and training of endodontists becomes important. Diagnosing, preventing and treating any pulpal complications are an integral part of endodontic training as are performing pulp regenerative procedures and treating inflammatory root resorption (Figure 8).

## Conclusion

Traumatic dental injuries present difficult challenges for both patients and their dentists. Current evidence allows the dental health care provider to manage situations that, in the past, often resulted in crippled dentition and unsightly appearance. Appropriate treatment can turn what at first glance looks like a hopeless situation into a very satisfactory outcome for patients. The endodontic specialist can play an important role in the team approach to treating patients with traumatic dental injuries.



**Fig. 8.** Inflammatory root resorption secondary to pulpal necrosis and infection in the pulpal space after avulsion. If diagnosed in time, it is possible to arrest the root resorption and maintain the tooth. (A) Extensive inflammatory root resorption on a tooth that was avulsed and reimplanted, but no further treatment done for six weeks. (B) Calcium hydroxide was placed in the tooth for three months. Apparent healing of the peri-root lesions and some reconstitution of a normal looking PDL.

## References

1. Diangelis AJ, Andreasen JO, Ebeleseder KA, Kenny DJ, Trope M, Sigurdsson A, et al. International Association of Dental Traumatology guidelines for the management of traumatic dental injuries: 1. Fractures and luxations of permanent teeth. *Dent Traumatol* 2012;28:2-12.
2. Andreasen JO, Ahrensburg SS, Tsilingaridis G. Root fractures: the influence of type of healing and location of fracture on tooth survival rates - an analysis of 492 cases. *Dent Traumatol* 2012;28:404-409.
3. Bucher K, Neumann C, Thiering E, Hickel R, Kuhnisch J. Complications and survival rates of teeth after dental trauma over a 5-year period. *Clin Oral Invest* 2013;17:1311-1318.
4. Hofman PA, Nelemans P, Kemerink GJ, Wilms JT. Value of radiological diagnosis of skull fracture in the management of mild head injury: meta-analysis. *J Neurol Neurosurg Psych* 2000;68:416-422.
5. McCrory P, Meeuwisse WH, Aubry M, Cantu RC, Dvorak J, Echemendia RJ, et al. Consensus statement on concussion in sport: the 4th International Conference on Concussion in Sport, Zurich, November 2012. *J Athl Train* 2013;48:554-575.
6. Fuss Z, Trowbridge H, Bender IB, Rickoff B, Sorin S. Assessment of reliability of electrical and thermal pulp testing agents. *J Endodon* 1986;12:301-305.
7. Skieller V. The prognosis for young teeth loosened after mechanical injuries. *Acta Odontol Scand* 1960;18:171-173.
8. About I, Murray PE, Franquin JC, Remusat M, Smith AJ. The effect of cavity restoration variables on odontoblast cell numbers and dental repair. *J Dent* 2001;29:109-117.
9. Murray PE, About I, Lumley PJ, Franquin JC, Windsor LJ, Smith AJ. Odontoblast morphology and dental repair. *J Dent* 2003;31:75-82.
10. Capp CI, Roda MI, Tamaki R, Castanho GM, Camargo MA, de Cara AA. Reattachment of rehydrated dental fragment using two techniques. *Dent Traumatol* 2009;25:95-99.
11. Cox CF, Bergenholz G, Fitzgerald M, Heys DR, Heys RJ, Avery JK, et al. Capping of the dental pulp mechanically exposed to the oral microflora – a 5 week observation of wound healing in the monkey. *J Oral Pathol* 1982;11:327-339.
12. Cvek M, Lundberg M. Histological appearance of pulps after exposure by a crown fracture, partial pulpotomy, and clinical diagnosis of healing. *J Endodon* 1983;9:8-11.
13. Cvek M. A clinical report on partial pulpotomy and capping with calcium hydroxide in permanent incisors with complicated crown fracture. *J Endodon* 1978;4:232-237.
14. Torabinejad M, Chivian N. Clinical applications of mineral trioxide aggregate. *J Endodon* 1999;25:197-205.
15. Andreasen FM, Noren JG, Andreasen JO, Engelhardt S, Lindh-Stromberg U. Long-term survival of fragment bonding in the treatment of fractured crowns: a multicenter clinical study. *Quintessence Intern* 1995;26:669-681.
16. Robertson A, Andreasen FM, Andreasen JO, Noren JG. Long-term prognosis of crown-fractured permanent incisors. The effect of stage of root development and associated luxation injury. *Int J Paediatr Dent* 2000;10:191-199.
17. Zachrisson BU, Jacobsen I. Long-term prognosis of 66 permanent anterior teeth with root fracture. *Scan J Dent Res* 1975;83:345-354.
18. Cvek M, Tsilingaridis G, Andreasen JO. Survival of 534 incisors after intra-alveolar root fracture in patients aged 7-17 years. *Dent Traumatol* 2008;24:379-387.
19. Alkhalifa JD, Alazemi AA. Intrusive luxation of permanent teeth: a systematic review of factors important for treatment decision-making. *Dent Traumatol* 2014;30:169-75.



20. Andreasen JO, Bakland LK, Andreasen FM. Traumatic intrusion of permanent teeth. Part 2. A clinical study of the effect of preinjury and injury factors, such as sex, age, stage of root development, tooth location, and extent of injury including number of intruded teeth on 140 intruded permanent teeth. *Dent Traumatol* 2006;22:90-98.
21. Andreasen JO, Bakland LK, Andreasen FM. Traumatic intrusion of permanent teeth. Part 3. A clinical study of the effect of treatment variables such as treatment delay, method of repositioning, type of splint, length of splinting and antibiotics on 140 teeth. *Dent Traumatol* 2006;22:99-111.
22. Kahler B, Heithersay GS. An evidence-based appraisal of splinting luxated, avulsed and root-fractured teeth. *Dent Traumatol* 2008;24:2-10.
23. Andreasen JO, Andreasen FM, Mejare I, Cvek M. Healing of 400 intra-alveolar root fractures. 2. Effect of treatment factors such as treatment delay, repositioning, splinting type and period and antibiotics. *Dent Traumatol* 2004;20:203-211.
24. Huang GT. A paradigm shift in endodontic management of immature teeth: conservation of stem cells for regeneration. *J Dent* 2008;36:379-386.
25. Trope M. Treatment of the immature tooth with a non-vital pulp and apical periodontitis. *Dent Clin N Am* 2010;54:313-324.
26. Wang C, Qin M, Guan Y. Analysis of pulp prognosis in 603 permanent teeth with uncomplicated crown fracture with or without luxation. *Dent Traumatol* [Epub ahead of print]: 2014
27. Blomlof L, Lindsog S, Hedstrom KG, Hammarstrom L. Vitality of periodontal ligament cells after storage of monkey teeth in milk or saliva. *Scand J Dent Res* 1980;88:441-445.
28. de Souza BD, Bortoluzzi EA, da Silveira Teixeira C, Felipe WT, Simoes CM, Felipe MC. Effect of HBSS storage time on human periodontal ligament fibroblast viability. *Dent Traumatol* 2010;26:481-483.
29. Hinckfuss SE, Messer LB. Splinting duration and periodontal outcomes for replanted avulsed teeth: a systematic review. *Dent Traumatol* 2009;25:150-157.
30. Lindsog S, Blomlof L, Hammarstrom L. Cellular colonization of denuded root surfaces in vivo: cell morphology in dentin resorption and cementum repair. *J Clin Perio* 1987;14:390-395.
31. Day P, Duggal M. Interventions for treating traumatised permanent front teeth: avulsed (knocked out) and replanted. The Cochrane database of systematic reviews 2010(1):CD006542.

The AAE wishes to thank Dr. Asgeir Sigurdsson for authoring this issue of the newsletter, as well the following article reviewers: Drs. Peter J. Babick, Leif K. Bakland, Steven J. Katz, Linda G. Levin and Robert S. Roda.

### Exclusive Online Bonus Materials: Traumatic Dental Injuries

This issue of the *Colleagues* newsletter is available online at [www.aae.org/colleagues](http://www.aae.org/colleagues) with the following *exclusive bonus materials*:

- AAE Recommended Guidelines for the Treatment of Traumatic Dental Injuries
- International Association of Dental Traumatology Dental Trauma Guidelines



## LIVE LEARNING CENTER

*Endodontic education online, on demand.*

Earn online CE credit when you enjoy two articles from **Colleagues for Excellence!**

[www.aae.org/LiveLearningCenter](http://www.aae.org/LiveLearningCenter)

*The information in this newsletter is designed to aid dentists. Practitioners must use their best professional judgment, taking into account the needs of each individual patient when making diagnosis/treatment plans. The AAE neither expressly nor implicitly warrants against any negative results associated with the application of this information. If you would like more information, consult your endodontic colleague or contact the AAE.*

*Did you enjoy this issue of Colleagues? Are there topics you would like to cover in the future? We want to hear from you! Send your comments and questions to the American Association of Endodontists at the address below, and visit the Colleagues online archive at [www.aae.org/colleagues](http://www.aae.org/colleagues) for back issues of the newsletter.*



©2014, American Association of Endodontists  
211 E. Chicago Ave., Suite 1100  
Chicago, IL 60611-2691

Phone: 800/872-3636 (U.S., Canada, Mexico) or 312/266-7255

Fax: 866/451-9020 (U.S., Canada, Mexico) or 312/266-9867

Email: [info@aae.org](mailto:info@aae.org) Website: [www.aae.org](http://www.aae.org)



[www.facebook.com/endodontists](http://www.facebook.com/endodontists)



@aaenews / @savingyourteeth



[www.youtube.com/rootcanalspecialists](http://www.youtube.com/rootcanalspecialists)